

Massimo Leandri  
Massimo Luzzani  
Alberto Gottlieb

## Trigeminal evoked potentials in cluster headache

Received: 27 January 2000

Accepted in revised form: 28 February 2000

M. Leandri (✉)  
Interuniversity Centre for Pain  
Neurophysiology,  
Department of Oncology, Biology  
and Genetics, University of Genoa,  
Via Dodecaneso 35, I-16146, Genoa, Italy  
e-mail: cind@unige.it  
Tel.: +39-010-3537081  
Fax: +39-010-3536960

M. Luzzani • A. Gottlieb  
Centre for Pain Relief  
National Institute for Cancer Research,  
Genoa, Italy

**Abstract** We sought out alterations of early trigeminal evoked potentials (TEPs) in patients suffering from episodic cluster headache, in order to evaluate a possible direct involvement of the trigeminal nerve. The study was carried out at the Centre for Pain Relief, National Institute for Cancer Research, Genoa in collaboration with the Interuniversity Centre for Pain Neurophysiology, unit of the University of Genoa. We studied 32 patients suffering from episodic cluster headache. TEPs were recorded from the scalp, after stimulation of the infraorbital nerve on both sides. The recordings were performed during the patients' bouts, but outside attacks in 24 cases. In 8 patients the recordings were

performed during attacks. All 8 patients tested during an attack showed a delayed or absent W2 and W3 of the TEP, while only 3 of the 24 patients tested outside the attack had delayed W2 and W3. The alterations detected point towards a temporary impairment of conduction along the nerve fibres, approximately at the gasserian ganglion. Such a situation is consistent with a moderate compression by a swollen internal carotid artery or cavernous sinus upon the ganglion, during the attack.

**Key words** Trigeminal evoked potentials • Cluster headache • Nerve conduction • Nerve block

### Introduction

Cluster headache is a recognized vascular headache syndrome, but its unilaterality, abrupt onset, and the occurrence of local vegetative signs suggest that a direct involvement of the trigeminal and autonomic nerves takes place. Besides possible activation of the trigeminovascular system by anomalous activity of the central nervous system [1, 2], it may be conceivable that abnormal activity within the trigeminal nerve is triggered by compression or inflammation of its trunk. No morphological abnormalities have ever been demonstrated in radiological studies of the parasellar region, except for a slight dilatation of the ophthalmic artery during the cluster attacks [3]. However functional studies might reveal more subtle alterations. Scalp-recorded, early trigeminal evoked potentials (TEPs) reflect the

activity of the maxillary nerve (component W1), the retro-gasserian root (component W2) and the presynaptic intrapontine fibres (component W3) [4, 5]. TEPs are sensitive to slight damage of the nerve, and at the same time reveal with a high degree of precision the site of the altered conduction [6, 7]. The aim of this study was to investigate whether altered conduction of the trigeminal nerve can be demonstrated in patients suffering from cluster headache, by means of TEPs.

### Material and methods

We studied 32 patients suffering from episodic cluster headache [8]. They were all male, ranging in age from 28 to 62 years, and had been

suffering from this condition for 2–12 years. All were subject to attacks characterized by symptoms of local sympathetic impairment and partial Horner's syndrome. They were studied during the bout period, which had lasted, until the moment of our test, between 7 and 42 days. The attack duration was between 15 and 60 minutes. Of these, 8 were studied during the attack (they received rescue treatment immediately after the recording, which only took 2–3 minutes to be performed), while the remaining 24 were studied in the inter-attack period.

Early TEPs were obtained using a technique previously described [9]. A short review of the basic method is given here, together with added details relevant to the present study. The infraorbital nerve was bilaterally stimulated by means of 0.05-ms electrical pulses, at a rate of 3/s, and an intensity between 0.1 and 1.2 mA, equivalent to 3 times the minimum intensity necessary to reach the sensory threshold. The pulses were delivered by two electrodes inserted into the infraorbital foramen.

TEPs were recorded from a surface EEG electrode placed on the vertex (Cz), with a reference on the neck (Cv7, i.e. seventh cervical vertebra). The signal was amplified 200 000 times with a 10–3000 Hz bandpass filter, then fed into a digital converter (1 MHz clock). An epoch of 10 ms was processed by averaging (500 points, 200–1000 responses) and stored into a computer database. Traces were then retrieved for accurate reading of amplitudes and latencies. Normality and abnormality of TEPs were defined according to data already published and obtained in the same laboratory [9]. According to these data, collected from a population of 96 healthy subjects, the mean value for the W1–W2 interval is  $0.93 \pm 0.09$  ms, indicating an upper limit of normality (mean plus 3 times the standard deviation) of 1.20 ms. The normal value for W1–W3 is  $1.64 \pm 0.17$  ms, with an upper limit of normality of 2.15 ms [9]. These intervals are not affected in a statistically significant way by age in the single subject, so they can safely be applied to a pathological population without the need for age-matching [9].

A clinical evaluation of sensory perception was performed immediately before and after the recording, by means of a cotton swab for tactile sensitivity, and a needle for pinprick. The painful and the healthy sides were both examined.

Informed consent was always obtained and the declaration of Helsinki was adhered to.

## Results

All 8 patients recorded during an attack had an altered TEP on the side of pain (Table 1). The alterations always included both the W2 and W3 components. These were either delayed or completely absent. In 3 of these cases we were able to perform a recording after the end of the cluster period, between approximately 1 and 2 months after the first test. This time we detected normal TEPs (data not shown). Though the number of cases is too small to show a correlation between degree of alteration and pain, the strongest attacks were accompanied by complete loss of W2 and W3 components. Delays of W2 (measured as the interval between W1 and W2) were in the range of 1.6–2.38 ms, whereas W3 was delayed from 2.47 to 3.19 ms (measured as the interval between W1 and W3). In one case (#4), by mere chance, we were able to record immediately before and during an attack. The response before the attack was within normal limits, whereas that during the attack showed loss of W2 and W3 (Fig. 1).

Of the 24 cases recorded outside the attack, only 3 had altered TEPs (Table 2). Alterations were represented by delays of W2 and W3, ranging from 1.37 to 1.46 ms for W2 and from 2.11 to 2.21 ms for W3. These 3 patients had their most recent attack 1–8 hours before the recording session. No relation was obvious between the TEP session-attack interval and the appearance of alterations.

No patient either during or outside the attack showed any impairment of sensory perception on the contralateral, healthy side.

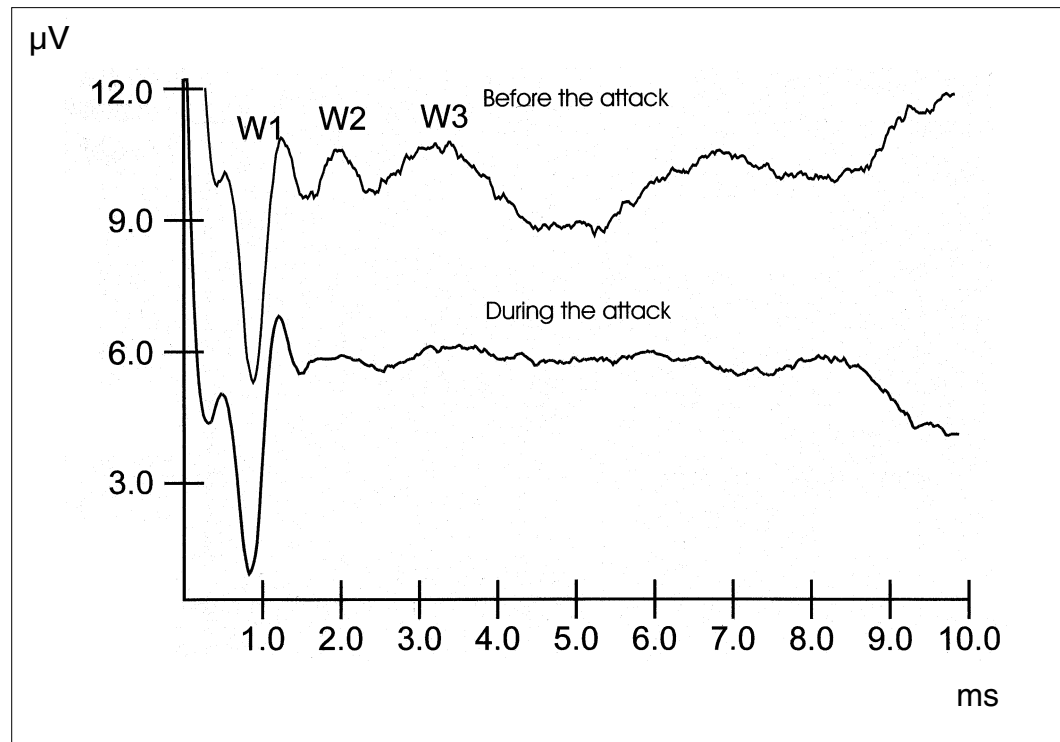
## Discussion

We have demonstrated that some important alterations of TEPs occur in patients affected by cluster headache. Three main issues arise from our findings.

**Table 1** TEPs recorded during an attack of cluster headache. The values correspond to the peak latency (ms) of each component. The delayed components are marked with an asterisk, whereas those missing are marked by a dash

Patient	Pain side	Right side			Left side		
		W1	W2	W3	W1	W2	W3
1	Left	0.92	1.79	2.53	0.98	–	–
2	Left	0.99	1.85	2.61	0.96	2.45*	3.43*
3	Right	1.02	3.40*	4.21*	0.98	1.81	2.52
4	Right	0.89	–	–	0.92	1.75	2.32
5	Left	1.00	1.56	2.73	0.96	2.56*	3.63*
6	Left	0.99	1.43	2.65	1.01	–	–
7	Left	0.91	1.41	2.55	0.94	2.64*	3.66*
8	Right	0.95	–	–	1.01	1.83	2.48

**Fig. 1** Early TEPs recorded in case #4. Both recordings were performed on the pain-affected side. The upper trace shows the recording performed approximately 15 minutes before the onset of the attack. All three components W1, W2 and W3 are visible and within normal limits. The lower trace shows the recording made during the attack. Only the W1 component is recognizable, indicating that impairment in conduction takes place at the gasserian ganglion



**Table 2** Cases of abnormal TEPs found in the 24 patients recorded outside the attack period. Delayed components are marked by an asterisk

Patient	Pain side	Right side			Left side		
		W1	W2	W3	W1	W2	W3
14	Left	0.90	1.80	2.54	0.98	2.35*	3.09*
22	Right	1.02	2.45*	3.23*	1.00	1.92	2.62
28	Left	0.95	1.84	2.49	0.94	2.40*	3.15*

First, early TEPs recorded with the method employed in the present work are the expression of activity elicited in fast-medium conducting fibres. These carry the tactile sensitivity. Smaller fibres, carrying thermal and pain sensitivity, do not contribute to the scalp-recorded TEPs, and nothing can be said about them from our findings. There is an apparent disagreement between the normal clinical sensory perception test and the TEP alterations. TEPs have a high sensitivity, and may be altered by otherwise subclinical lesions [6, 7]. Therefore, it is possible that in our cases a small lesion may have impaired the TEPs but not the sensory perception.

Second, early TEPs have a good localizing power. By simultaneously recording the TEP scalp response and the nerve activity during neurosurgical procedures, it has been demonstrated that W1 takes origin from the maxillary nerve at the foramen rotundum, W2 from the middle portion of the

retrogasserian root, and W3 from inside the pons [4, 5]. As our results show that W2 and W3 components are delayed or absent, while W1 is within normal limits, it is obvious that the site of altered conduction is located between the site of origin of W1 and that of W2, which points towards the gasserian ganglion and its immediate surroundings. One may note that we evoked early TEPs by stimulating the infraorbital nerve in a disorder that mainly involves the first trigeminal division. From a practical point of view, as previously stated [6, 7, 9], the infraorbital evoked TEPs are the only type with a high level of accuracy and reproducibility. On the other hand, these responses are sensitive enough to detect damage primarily involving the first or third division and only indirectly involving the second division [6, 7].

Third, TEPs recorded during the attack were always altered, whereas those studied outside the attack were usually normal. We conclude that during the attack a functional and

temporary impairment of conduction takes place at the gasserian ganglion on the side of pain. Convincing evidence of this train of events is given by the recordings from case #4, in which a normal TEP, recorded immediately before, was followed by an abnormal TEP recorded during the attack (Fig. 1).

Summing up, the electrophysiological evidence points towards an impairment of conduction taking place at the gasserian ganglion during the attack. The close spatial relationship between the internal carotid artery, the cavernous sinus and the gasserian ganglion may well justify a slight compression of the latter by dilatation of the involved vessels [1]. It is therefore conceivable that a reversible nerve block [10] takes place, usually only temporarily. The long-lasting alterations seen in the 3 patients may be explained

either by myelin sheath or axonal damage due to a particularly serious compression of the ganglion, or by a transient, reversible nerve block due to a slight, but long-lasting impingement of the carotid artery upon the ganglion. The latter condition would be similar to that affecting the trigeminal nerve root in trigeminal neuralgia [11].

Although the pain characteristics of cluster headache and trigeminal neuralgia are different, the evidence of direct involvement of the gasserian ganglion during the cluster attack leads to the hypothesis that the two conditions may share some causative mechanisms.

**Acknowledgements** This study was supported by the project "Pathophysiology of cluster headache" from MURST, Italy.

## References

1. Hardebo JE, Moskowitz MA (1993) Synthesis of cluster headache pathophysiology. In: Olesen J, Tfelt-Hansen P, Welch KMA (eds) *The headaches*. Raven, New York, pp 569–576
2. Goadsby PJ, Edvinsson L (1994) Human in vivo evidence for trigemino-vascular activation in cluster headache. Neuropeptide changes and effects of acute attack therapies. *Brain* 117:427–434
3. Waldenlind E, Ekbom K, Torhall J (1993) MR-angiography during spontaneous attacks of cluster headache: a case report. *Headache* 33:291–295
4. Leandri M, Campbell JA (1986) Origin of early waves evoked by infraorbital nerve stimulation in man. *Electroencephalogr Clin Neurophysiol* 65:13–19
5. Leandri M (1998) Generator sites of early scalp potentials evoked from the three trigeminal branches. *J Neurosurg* 88:718–725
6. Leandri M, Parodi CI, Favale E (1988) Early trigeminal evoked potentials in tumours of the base of the skull and trigeminal neuralgia. *Electroencephalogr Clin Neurophysiol* 71:114–124
7. Leandri M, Favale E (1991) Diagnostic relevance of trigeminal evoked potentials following infraorbital nerve stimulation. *J Neurosurg* 75:244–250
8. Headache Classification Committee of the International Headache Society (1988) Classification and diagnostic criteria for headache disorders, cranial neuralgias and facial pain. *Cephalalgia* 8[Suppl 7]:35–38
9. Leandri M, Parodi CI, Favale E (1988) Normative data on scalp responses evoked by infraorbital nerve stimulation. *Electroencephalogr Clin Neurophysiol* 71:415–421
10. Schaumburg HH, Spencer PS, Thomas PK (1983) *Disorders of peripheral nerves*. Davis, Philadelphia
11. Leandri M, Eldridge P, Miles JB (1998) Recovery of nerve conduction following microvascular decompression for trigeminal neuralgia. *Neurology* 51:1641–1646